

Appendicitis US Protocol

Reviewed By: Sarah Farley, MD; Shireen Khan, MD; Spencer Lake, MD
Last Reviewed: June 2019

Contact: (866) 761-4200

****NOTE for all examinations:**

1. CINE clips to be labeled:

-MIDLINE structures: “right to left” when longitudinal and “superior to inferior” when transverse

-RIGHT/LEFT structures: “lateral to medial” when longitudinal and “superior to inferior” when transverse

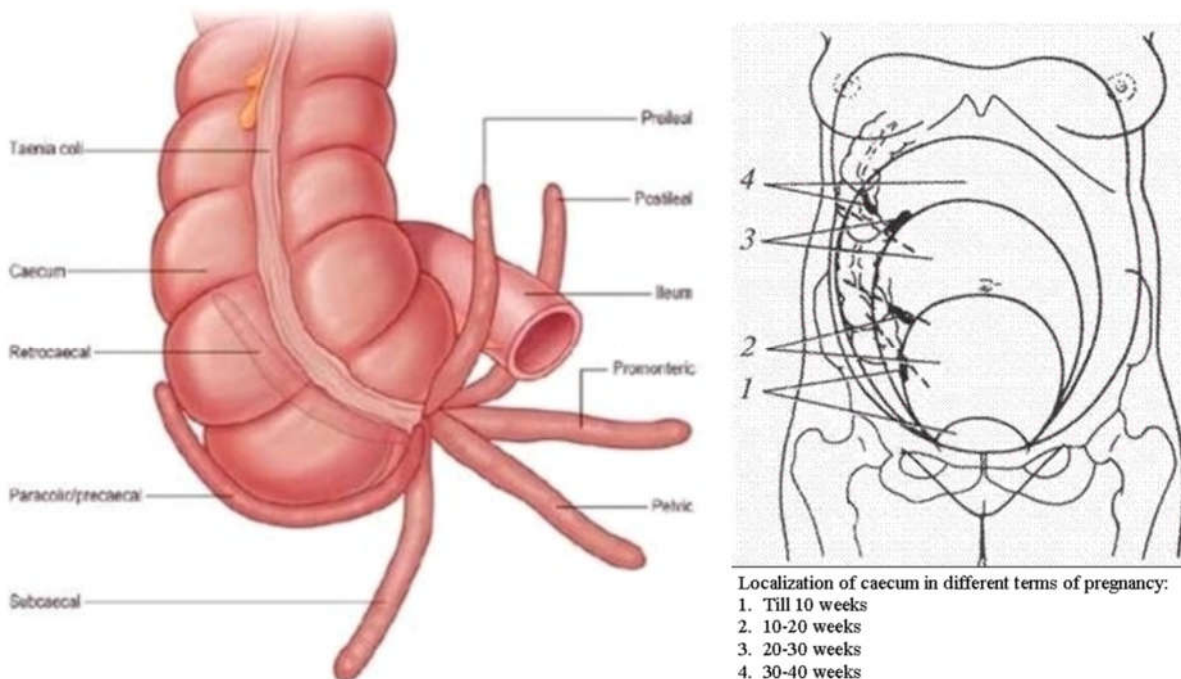
each should be 1 sweep, NOT back and forth

General

The appendix can be located anywhere in the right abdomen from the liver to the deep pelvis, from lateral of the ascending colon to the midline near the umbilicus. In pregnant patients, the appendix is often displaced into the right upper quadrant.

The key to successful scanning is to identify the cecum and focus attention on the likely location of the appendix.

When the appendix is inflamed, secondary findings of echogenic fat (inflammation) and fluid may be present to assist in locating the appendix. However, a normal appendix can be more challenging.



TRA-MINW

Strategies for finding the appendix include:

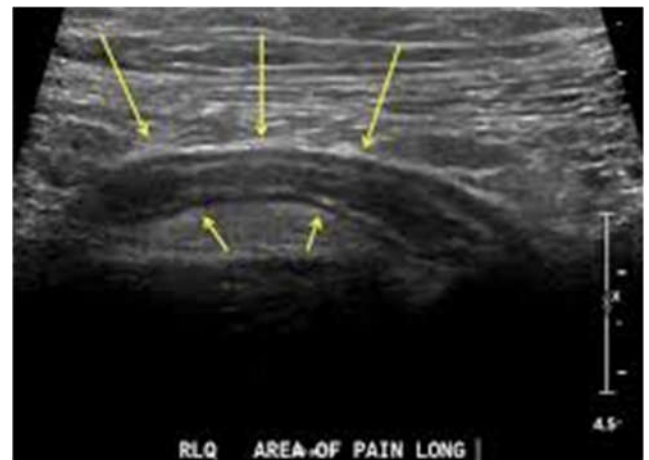1. Review prior CT abdomen/pelvis or appendix US to see where appendix has been previously.
2. Scan in area of greatest pain (indicated by focal tenderness by 1 finger, not general pain). Label as such.
3. Localize cecum.
4. Localize ileocecal valve, if possible.

Equipment:

1. Linear high frequency transducer is **required**, as this will best demonstrate anatomy of appendix.
2. In larger or obese patients, a *curved lower frequency transducer* may be used to obtain an overview and localize the cecum first. THEN, switch to the linear probe.
 - a. When you locate the appendix, **turn ON harmonics** to better visualize the walls and appendiceal lumen together.
 - i. For GE machines, use the linear 9 MHz under LEV setting for better penetration in larger body habitus.
 - b. Very rarely the linear probe will not be useful if the appendix is perforated and/or a complex abscess or phlegmon is present.
 - i. Optimize probe and settings, as necessary

Approach + Technique:

- 1) If the patient can point with 1 finger to site of focal tenderness, scan there first. You may get lucky.
 - a) Label this area as site of focal pain.
- 2) If the patient did not point to right lower quadrant, scan where he/she is pointing.
- 3) The appendix is often draped over the iliac vessels.
 - a) The appendix is most often here but not always
 - b) If the appendix is not readily visualized, you will need to search in a thorough and predictable pattern



SEARCH PATTERN (if appendix is not easily seen) – TIPS:

1. With patient still supine, scan in transverse plane from inferior liver along right abdomen visualizing the colon and keeping the lateral abdominal wall in view (appendix can be lateral to colon - don't want to miss it).

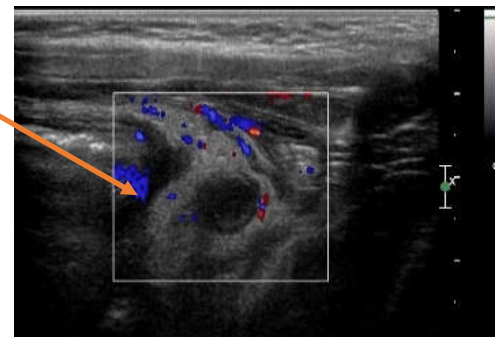
TRA-MINW

- a. Scan from superior to inferior (RUQ to pelvis) moving centrally as you run into the iliac crest just above the groin.
 - i. May need to scan BOTH along lateral and then along medial aspect of ascending colon.
 - ii. The colon can be recognized by the gas and stool pattern. Once identified, follow the ascending colon to the end. This is cecum.
 - (1) Remember the cecum may go deep into the pelvis or turn medially toward the midline. This may require switching to a different probe.
 - (2) Along the way you may or may not see the ileocecal valve.
 - (a) You may need to apply pressure to move any small bowel loops out of the way. Gentle manual pressure in the RLQ while scanning can also help.
 - a. Once you locate the cecum, scan in multiple planes through the cecum to try to identify a structure that looks like the appendix.
2. If the appendix is still not seen, lay the patient LEFT lateral decubitus and scan transverse from iliac crest up to inferior pole right kidney.
 - a. Can also apply gentle manual pressure to RLQ to move bowel loops.
3. If you are still having difficulty finding the appendix, have the patient empty bladder and attempt bowel movement/pass gas – this can move gas/bowel away from area of interest.
 - a. Try above tips again after patient has voided/defecated.

HOW WILL YOU KNOW IT IS APPENDIX?

1. The appendix is a tubular, blind ending structure originating from the cecum.
 - a. Once you find something that looks like the appendix, your job is to convincingly prove that it originates from the cecum (by following it back to the cecal origin) and to *prove that it is blind ending*.
 - a. **Longitudinal and transverse CINEs all the way through the blind ending tip are most convincing.**

2. An abnormal appendix is enlarged and noncompressible.
 - a. Often has surrounding echogenic fat and possibly fluid around it
 - i. Echogenic fat around an enlarged hyperemic appendix is a sign of inflammation.



3. Once found:
 - a. **Measurements of appendix (outer wall to outer wall) should be obtained at 3 points: base, mid and tip.**
 - i. As always, optimize depth and focal zone settings first
 - b. Check for blood flow

TRA-MINW

- c. Document any appendicoliths with measurements
 - d. Assess compressibility (in the base, mid and tip)
4. If the appendix seems to dive into the pelvis and the tip is not seen, try a different probe.
- a. Is it really the appendix?
 - i. *Could it be small bowel?*
 - ii. If you can identify the ileocecal valve above the appendiceal origin that can be helpful for confirmation.
5. Evaluate for lymph nodes in the region.
- a. Document abnormal nodes (short axis > 8 mm)
6. Evaluate for fluid in the region.
- a. Document if simple or complex
-

Required Images:

This protocol applies only to pediatric patients (<18 years old), pregnant patients, and non-pregnant adults with BMI <25. Appendix ultrasound is of lower diagnostic yield in adult patients with BMI \geq 25. Ordering clinicians wanting to make exceptions to this BMI cutoff will need to discuss the case with a radiologist prior to the exam.

Please note, a standalone appendix ultrasound exam requires no patient preparation (i.e., patient does not need to be fasting or have bladder prep). If a dedicated female pelvis ultrasound is ordered concurrently, bladder prep should be performed according to the female pelvis protocol, and images of the pelvic organs should be obtained prior to letting the patient void.

The following items should be imaged in addition to the appendix, and are best evaluated with curvilinear probe:

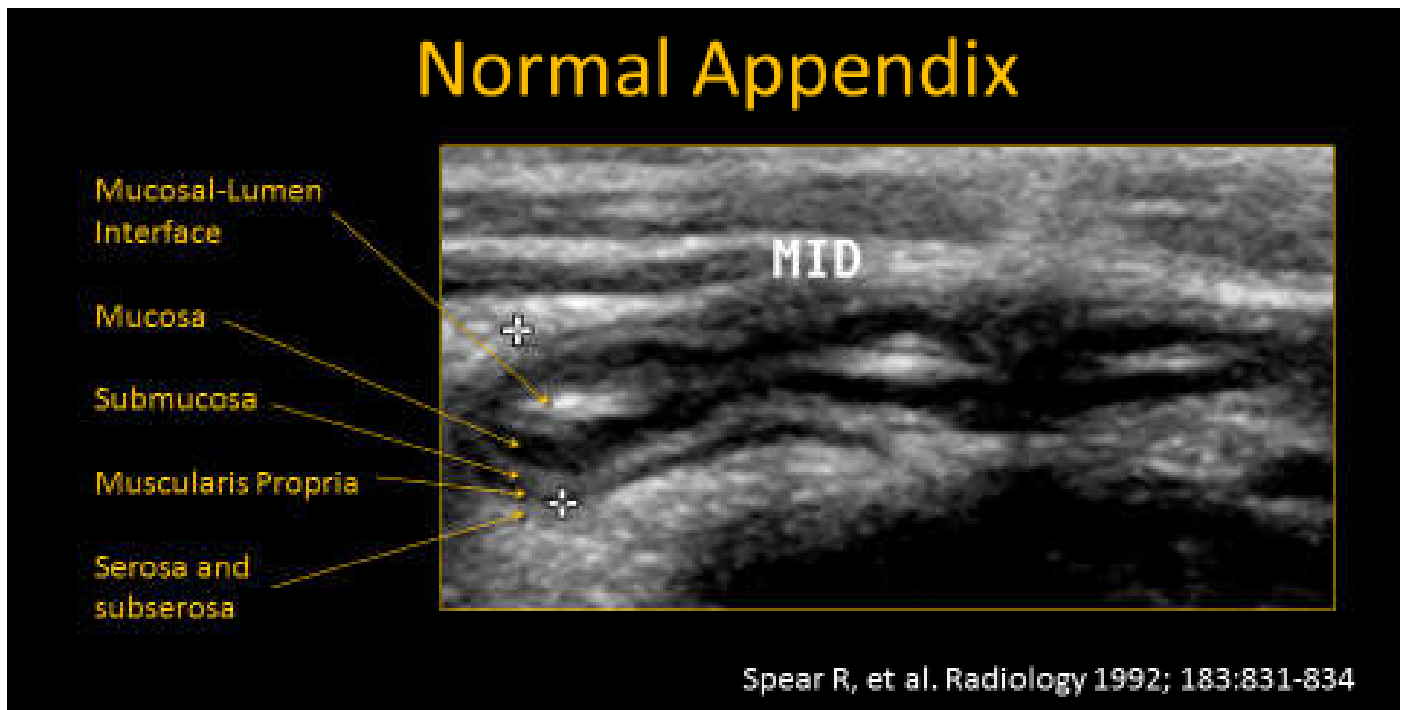
- A. One transverse image of the urinary bladder
- B. One sagittal image of the urinary bladder
- C. One long axis image of right kidney
- D. One longitudinal view of the gallbladder
- E. If female patient and urinary bladder is sufficiently full, attempt to locate the right ovary.
 - Include caliper measurements in 3 dimensions
 - Document arterial and venous spectral Doppler waveforms, if able

Additional images should be obtained as needed to more clearly define anatomy and/or to demonstrate pathology.

TRA-MINW

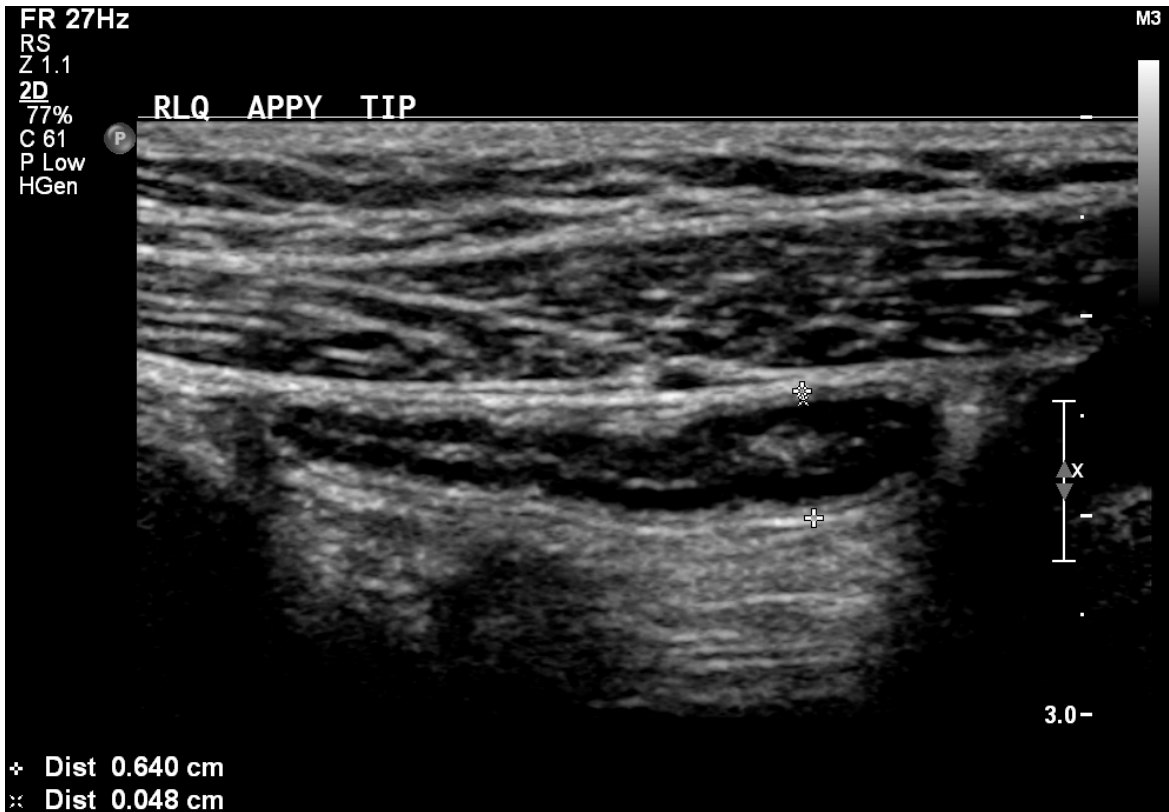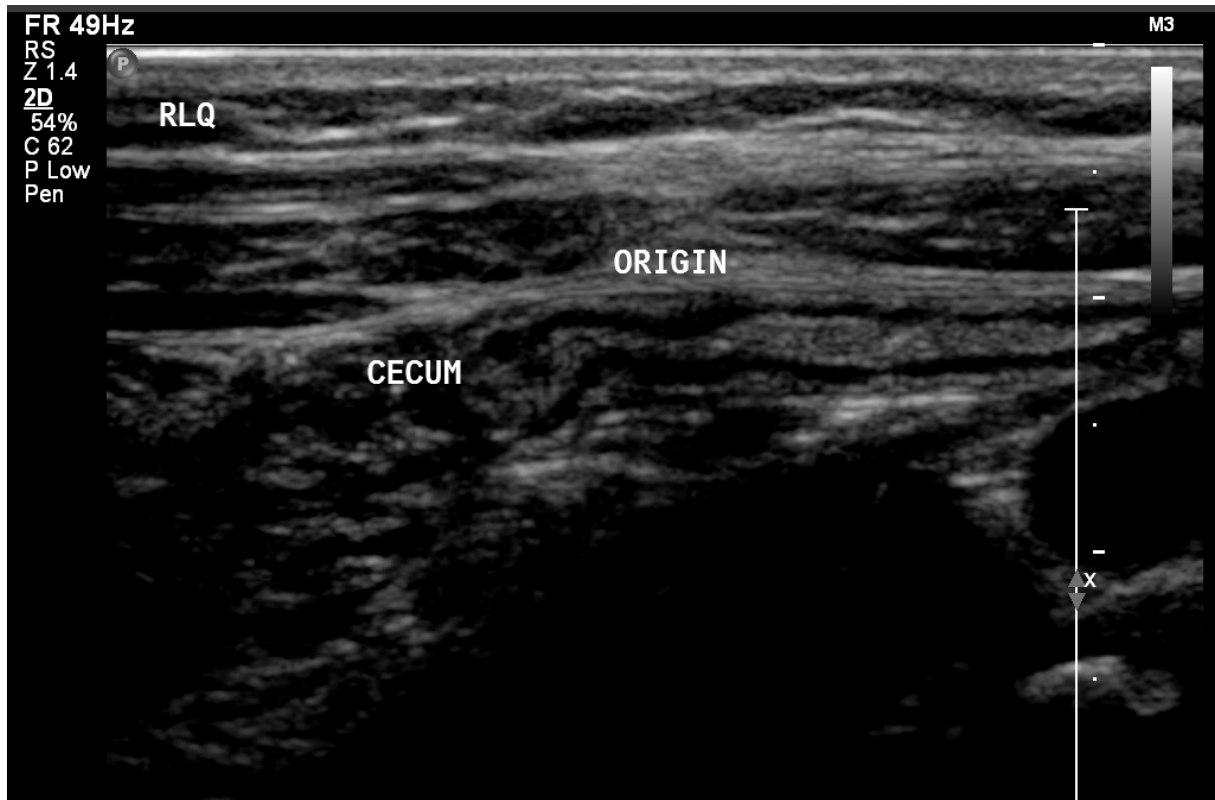
1. Longitudinal and transverse STILL images of appendix, especially of the tip to prove it is a blind ending structure. Measurements should be provided on longitudinal images with attention to avoid obliquity, measuring from the outer hypoechoic layer to the outer hypoechoic layer (i.e., muscularis propria). Include measurement of each:

- a. Origin from cecum (i.e., base)
- b. Mid appendix
- c. Tip of appendix



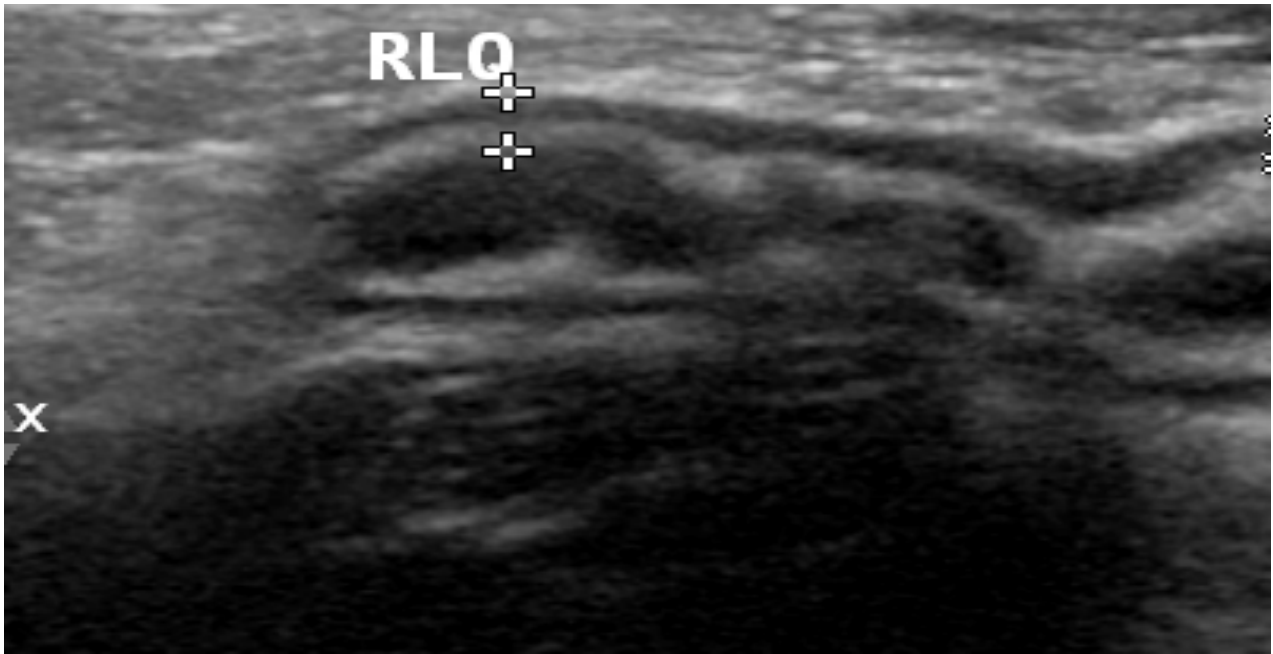
TRA-MINW

Normal Appendix

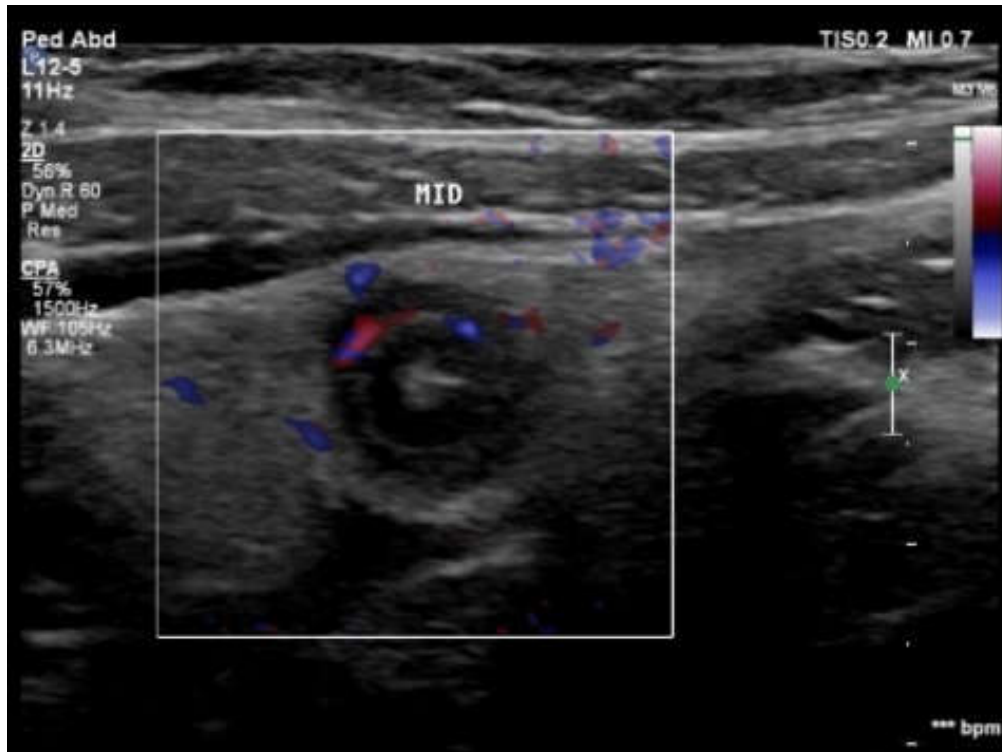


TRA-MINW

2. Wall measurement – **outer edge** of hypoechoic muscularis propria **to inner edge** of hyperechoic submucosa.

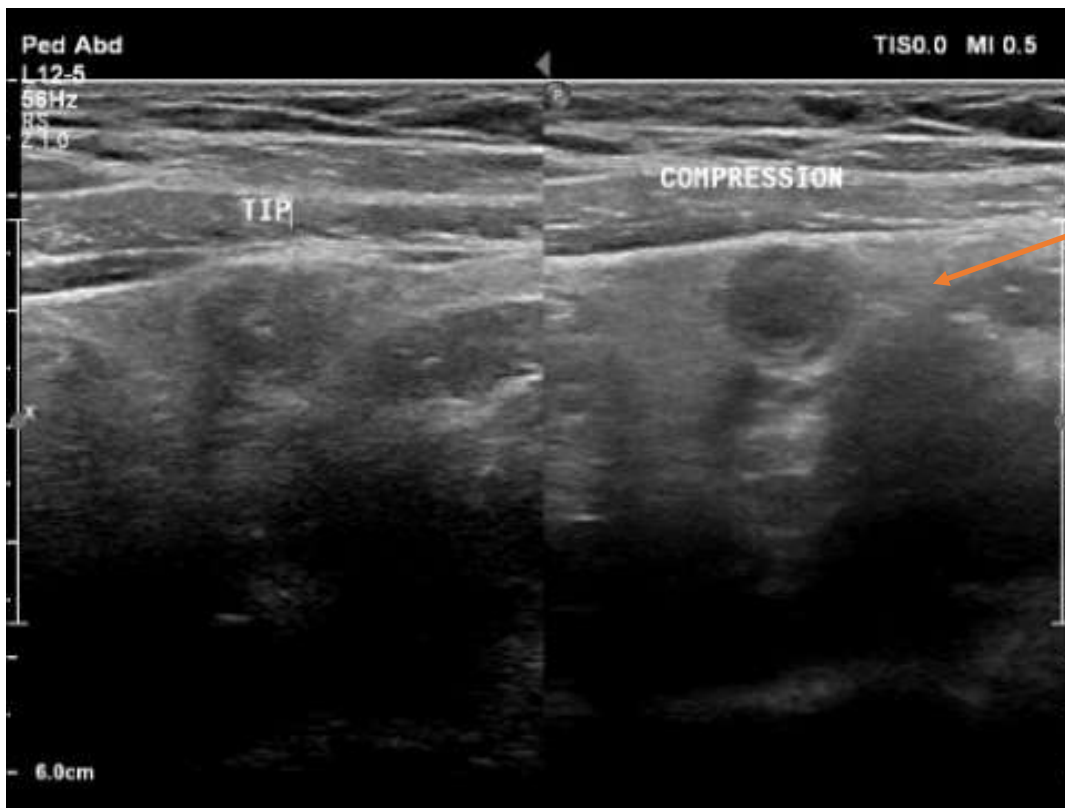


3. Include transverse images of appendix with color Doppler to assess for hyperemia.
 - a. Optimize Doppler settings.



TRA-MINW

- Split image of appendix without and with compression.

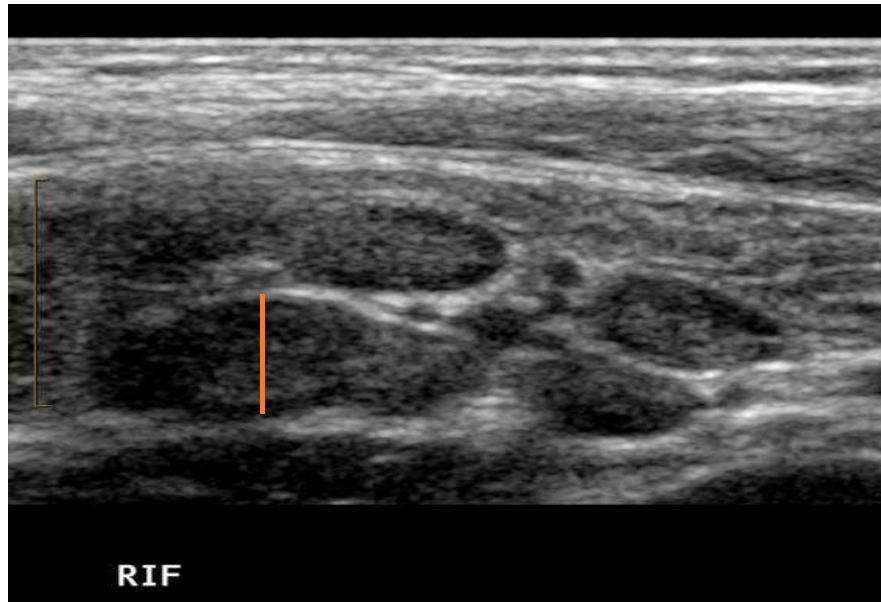


Note echogenic fat around appendix.

- Transverse CINE** from liver margin to beyond cecal tip (superior to inferior)
 - Ideally: Ascending colon at the edge of the screen throughout the CINE
 - May need 1 more lateral and 1 more medial to cover entire region (depending on patient factors)
- Longitudinal CINE** through cecal tip. This should be performed from lateral to medial.
- If appendix seen:** CINE (multiple planes, as necessary) to demonstrate *without a doubt* that this is indeed the appendix (cecal origin, tubular, blind-ending). At LEAST:
 - Clip showing appendix from origin to tip in transverse view
 - Clip showing tip in sagittal view to document blind ending
- If appendix is NOT seen:** multiple images/CINEs around cecum
 - Add anything relevant, i.e., echogenic fat/inflammation or fluid collections

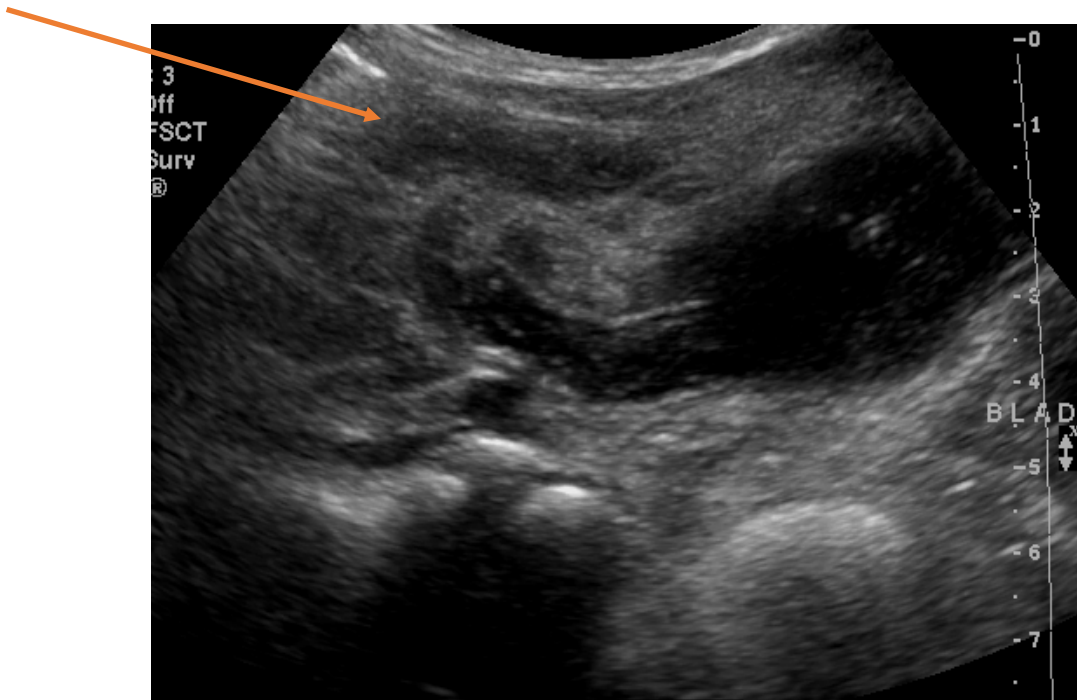
TRA-MINW

9. Only measure **abnormal** mesenteric lymph nodes: short axis > 8 mm



10. **Remain aware of other unexpected findings:** Ureteral stone, ovarian torsion, hydrosalpinx, intussusception, bowel wall thickening.

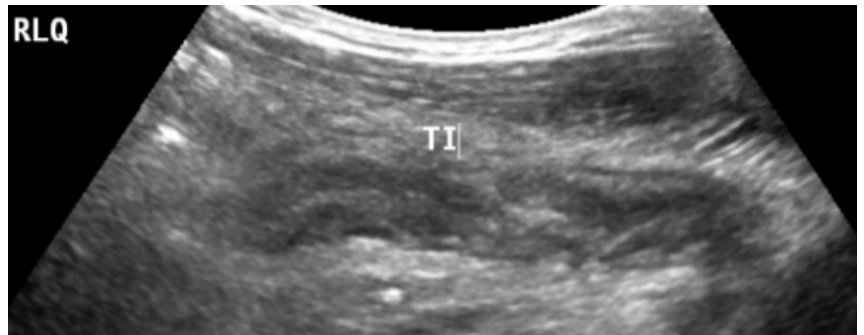11. Periappendiceal fluid collection can be a sign of a perforated appendix.



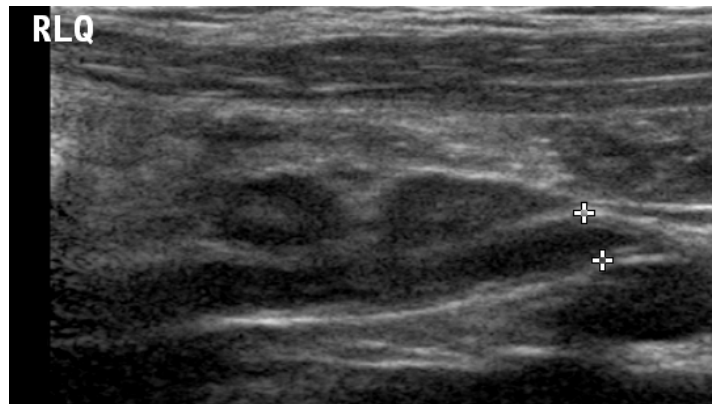
TRA-MINW

Pitfalls:

1. Decompressed terminal ileum can be mistaken for appendix. As such, do **not** *only* track bowel structure (i.e., possible TI) back to cecum and assume it is appendix. **Try to find and then document the blind ending tip.**



2. Dilated ureter can have peristalsis but will look different from bowel: no gut signature, usually linear or nearly linear, and contains simple fluid. Attempt to trace superiorly toward kidney or inferiorly toward bladder if ureter is suspected.



3. Gangrenous appendix can have loss of normal wall structure and can be confusing.

